

How does bimaxillary orthognathic surgery change dimensions of maxillary sinuses and pharyngeal airway space?

Luiza Roberta Bin^a; Liogi Iwaki Filho^b; Amanda Lury Yamashita^c; Gustavo Nascimento de Souza Pinto^d; Rui Amaral Mendes^e; Adilson Luiz Ramos^b; Isolde Terezinha dos Santos Previdelli^f; Lilian Cristina Vessoni Iwaki^b

ABSTRACT

Objectives: To assess changes in the maxillary sinus (MS) and pharyngeal airway space (PAS) after bimaxillary orthognathic surgery using cone-beam computed tomography (CBCT).

Materials and Methods: The CBCT scans of 48 patients were divided into two groups: group 1: maxillary advancement and mandibular setback ($n = 24$); group 2: maxillomandibular advancement ($n = 24$). The CBCTs were acquired 1 to 2 months preoperatively and 6 to 8 months postoperatively. A kappa test was used to determine intra- and interexaminer agreement. Area, volume, and linear measurements of MSs and PASs obtained before and after surgery were compared using a mixed model ($P < .05$).

Results: All variables of the MS showed significant postsurgical reductions in both groups, except the MS length, which showed a significant increase in group 2. Volume and minimum axial area of PAS showed statistically significant postsurgical increases in both groups ($P < .05$).

Conclusions: Despite the reduction in the MS and the increase in the PAS, results indicated that the airway was not negatively affected after maxillomandibular advancement and maxillary advancement with mandibular setback. (*Angle Orthod.* 2020;90:715–722.)

KEY WORDS: Orthognathic surgery; Maxillary sinus; Pharyngeal airway space; cone-beam computed tomography

INTRODUCTION

The maxilla and mandible are occasionally affected by developmental or growth problems causing unilateral, bilateral, horizontal, vertical, and/or transverse abnormalities.¹ Treatment of dentofacial deformities usually requires combined surgical orthodontics to restore the function and esthetics of the maxillofacial complex.^{1,2} For each deformity, a specific surgical treatment plan is created and may require surgical repositioning of one or both jaws.³

It might seem logical that maxillary surgery affects the morphology of structures such as the maxillary sinuses (MSs),⁴ which are important for breathing and speech resonance.⁵ Surgical movements of the maxilla (impaction or advancement) have been shown to affect their morphology^{2,6} as well as trigger inflammatory changes leading to mucosal thickening of the MS.⁷ Likewise, the pharyngeal airway space (PAS) also has particular anatomical traits that may undergo changes after orthognathic surgery due to its strong and muscular envelope and its relationship to surrounding structures (tongue, soft palate, and pharynx).^{7–9}

^a Graduate Oral and Maxillofacial Surgery Resident, Department of Dentistry, State University of West Parana, Cascavel, Paraná, Brazil.

^b Associate Professor, Department of Dentistry, State University of Maringá, Maringá, Paraná, Brazil.

^c Graduate Oral Radiology Resident, Department of Dentistry, State University of Maringá, Maringá, Paraná, Brazil.

^d Postgraduate Student, Department of Oral Diagnosis, Area of Oral Radiology, Piracicaba Dental School, University of Campinas, Piracicaba, São Paulo, Brazil.

^e Adjunct Professor, Department of Oral and Maxillofacial Medicine and Diagnostic Sciences, Case Western Reserve University, Cleveland, Ohio; and Center for Research in Higher Education Policies, Porto, Portugal.

^f Associate Professor, Department of Statistics, State University of Maringá, Maringá, Paraná, Brazil.

Corresponding author: Dr Lilian Cristina Vessoni Iwaki, Department of Dentistry, State University of Maringá, Avenida Mandacarú, No. 1550, Maringá 87080-000, Paraná, Brazil (e-mail: lilianiwaki@gmail.com)

Accepted: April 2020. Submitted: December 2019.

Published Online: June 25, 2020

© 2020 by The EH Angle Education and Research Foundation, Inc.

Whereas single-jaw surgery is a valid option for treating dentofacial deformities, some authors regard bimaxillary orthognathic surgery as an adequate alternative in Class II patients, since maxillomandibular advancement produces a gain in the PAS.¹⁰ Additionally, bimaxillary surgery is also considered a better choice for the management of Class III patients due to the more favorable effects on the PAS compared with mandibular setback alone.^{11–13}

Concerning the postsurgical outcomes, attention has focused on the onset of sinusitis¹⁴ and postsurgical changes in the PAS^{10,13} occurring in the orthognathic patient. Even though maxillary surgery requires knowledge of the anatomical variations of the facial sinuses,¹⁵ the literature is still scarce regarding the effects of orthognathic surgery on the MS.^{2,4,6} Thus, the aim of this study was to assess the changes in the MS and PAS after bimaxillary surgery using cone-beam computed tomography (CBCT). The null hypothesis was that bimaxillary surgery would not change the MS and PAS dimensions.

MATERIALS AND METHODS

Study Design

This retrospective cohort study was approved by the Committee on Ethics in Research Involving Human Beings at State University of Maringá, Brazil (CAAE: 55110916.5.0000.0104). The results of this study are reported according to the STROBE (Strengthening the Reporting of Observational Studies in Epidemiology) guidelines.¹⁶

The inclusion criteria were adult patients (18–50 years old) with Class II (ANB angle $>4^\circ$) and III (ANB angle $<0^\circ$)¹⁷ dentofacial deformities treated with bimaxillary orthognathic surgery between 2014 and 2016. While different professionals provided pre operative and postoperative orthodontics, a team of experienced surgeons was responsible for all operations. Exclusion criteria were patients with craniofacial syndromes,^{1,2} paranasal surgery before the orthognathic procedures,⁶ and MS^{4,18} and PAS⁸ pathologies.

Sample size was calculated with the mixed model, at a significance level of 5%, power of 80%, and the effect size of 0.5, resulting in 24 patients per group. The sample was divided into two groups according to the planned surgical movements⁸: group 1: maxillary advancement and mandibular setback (n : 24); group 2: maxillomandibular advancement (n : 24). All mandibular advancements and setbacks were performed with bilateral sagittal split osteotomy, while maxillary advancement was achieved through Le Fort I osteotomy.¹⁹ Functionally stable internal fixation was used in all operations.

Data Collection

The CBCT scans were performed up to 1 month preoperatively (T_0) and 6¹ to 8^{8,20} months postoperatively (T_1) with the i-CAT Next Generation (Imaging Sciences International, Hatfield, Pa) equipment by a single radiologist. The volumes were acquired with 0.300 mm voxel size, 17 × 23 cm field of view, tube voltage of 120 kVp, and tube current of 3–8 mA. According to a standard protocol, patients remained seated during scanning and were instructed to adopt the natural head position^{6,8,10} with the tongue and lips at rest,^{10,20} breathing lightly and without swallowing.^{2,10,13} The CBCT image files were exported in DICOM (Digital Imaging and Communication in Medicine) format into Dolphin Imaging software version 11.95 (Dolphin Imaging & Management Solutions, Chatsworth, Calif). Two calibrated examiners analyzed 10 random CBCTs that were measured twice with an interval of 15 days. To transfer CBCT images to the virtual workspace within Dolphin, the Frankfort horizontal plane (FH) of each head reconstruction was positioned to coincide with the software's axial plane, while the facial midline was coincident with the midsagittal plane, which in its turn was perpendicular to FH and included the nasion point.¹⁰ In cases of asymmetry, orientation was performed so that these planes were as close as possible to the original orientation planes.¹⁰ In sagittal reconstruction, the sella turcica (S) point at T_0 was used as a reference to draw the horizontal reference line (HRL) parallel to FH, and the vertical reference line (VRL) perpendicular to FH.

Using the side-by-side superimposition tool in Dolphin 3D software, T_0 and T_1 three-dimensional (3D) images were approximated using three neurocranial reference points located at glabella and the right and left frontal zygomatic sutures (Figure 1A). Then, the cranial base was superimposed, being defined by a red box in the coronal, sagittal, and axial reconstructions using the voxel-based superimposition tool (Figure 1B). Using this technique, Dolphin software combined the voxels in the defined area and automatically superimposed both images. The precision of the Dolphin 3D superimposition was then verified using the three reconstructions.²¹

For quantification of the surgical movements, four cephalometric points were used in the sagittal reconstructions: posterior nasal spine (PNS), point A (maxilla), point B (mandible), and menton (Me). With the HRL and VRL defined as the references, four horizontal and four vertical measurements were performed from PNS, A, B, and Me to HRL and VRL⁸ (Figure 2A,B). All measurements were performed at T_0 and then repeated at T_1 . All variables of MS were measured on both sides. In coronal reconstruction, MS

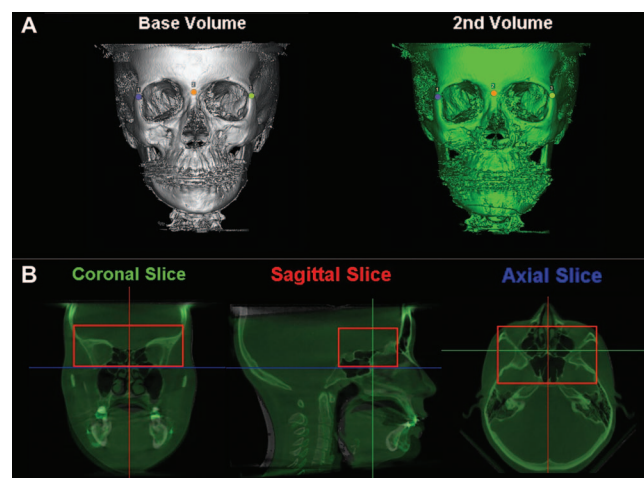


Figure 1. (A) Three anatomic references at T₀ (baseline volume) and T₁ (second volume) on three-dimensional images; (B) Voxel-based image superimposition on the cranial base (red box), which was used as a reference for superimposition in the three reconstructions.

areas were defined at the largest identifiable dimensions (Figure 3A). In addition, a line was drawn from the highest to the lowest points of MS to determine the maximum height^{22,23} (Figure 3B). In axial reconstruction, maximum lengths were defined as a line connecting the most anterior and posterior points of MS^{2,23} (Figure 4A) and, for the width, a line was drawn from the middle wall of the MS to the farthest lateral point, following the zygomatic arch (Figure 4B).

For the volume (mm³) of MS (Figure 5A–C) and PAS (Figure 6A–C), the Dolphin sinus/airway tool was used to delimit the structures of MS and PAS in the three reconstructions. The seed-points tool was used to select the area of interest. The threshold was standardized at a value of 41 ± 2 .¹⁰ For the volume of PAS, the upper limit was a line connecting PNS to

basion point; the lower limit, a line from the lowest point of the epiglottis to the most anteroinferior point of the third cervical vertebra; the posterior border, the posterior PAS wall; and the anterior border, the anterior PAS wall^{8,10} (Figure 6C). When measuring the total volume, the tool option that automatically delivered the minimum axial area (MAA) within the predetermined PAS was selected (Figure 6C). The MAA (mm²) was the smallest cross-sectional area of any predefined PAS, that is, the area of greatest PAS constriction. For more detailed analysis, the PAS was divided into upper (Figure 6A) and lower (Figure 6B) segments by a line connecting the most posteroinferior point of the soft palate to the lowest point of the second cervical vertebra.¹⁰

Outcome and Predictor Variables

The primary outcome variables were measurements of MS (area, volume, height, width, length) and PAS (total volume, upper PAS volume, lower PAS volume, MAA) to observe the effect of the orthognathic surgery. Sides (right and left) were selected as the predictor variables in MS as well as time points (CBCTs T₀ and T₁) and groups (1 and 2) for MS and PAS. The surgical variables (H-PNS, V-PNS, H-A, and V-A) were the secondary outcome variables.

Statistical Analysis

The Shapiro-Wilk test was performed to test data normality, while the Kappa test was used to determine intraexaminer and interexaminer agreement. A mixed model with multilevel modeling was used to evaluate each outcome variable of MS and PAS in both groups, being a two-level model for MS and one-level model for PAS. In the mixed model, covariates were also used as

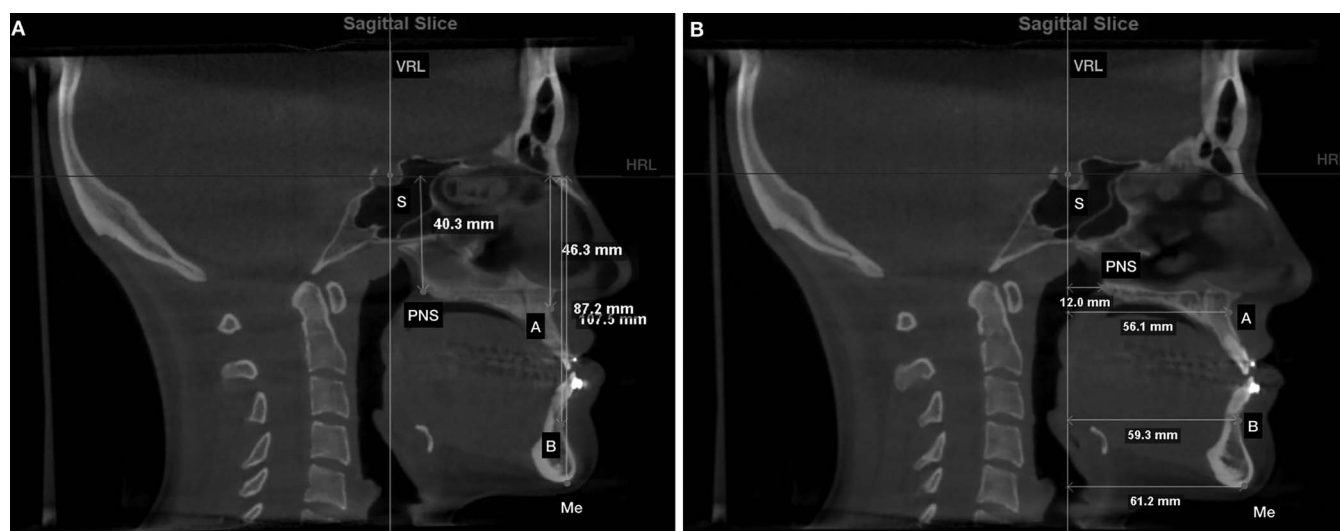


Figure 2. Measurements of surgical movements in sagittal reconstruction. (A) Vertical surgical movements. (B) Horizontal surgical movements.

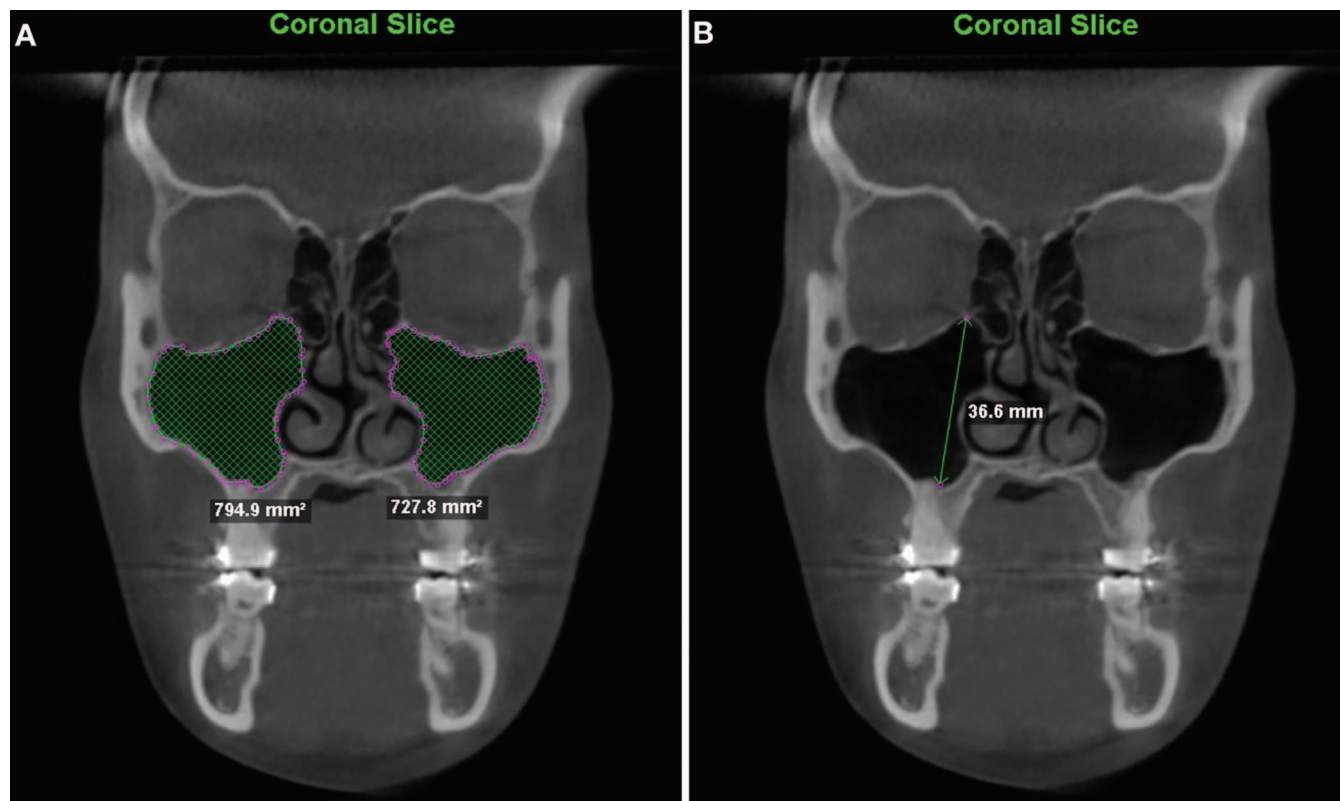


Figure 3. Measurements of maxillary sinus (MS) in coronal reconstruction. (A) MS area. (B) MS height.

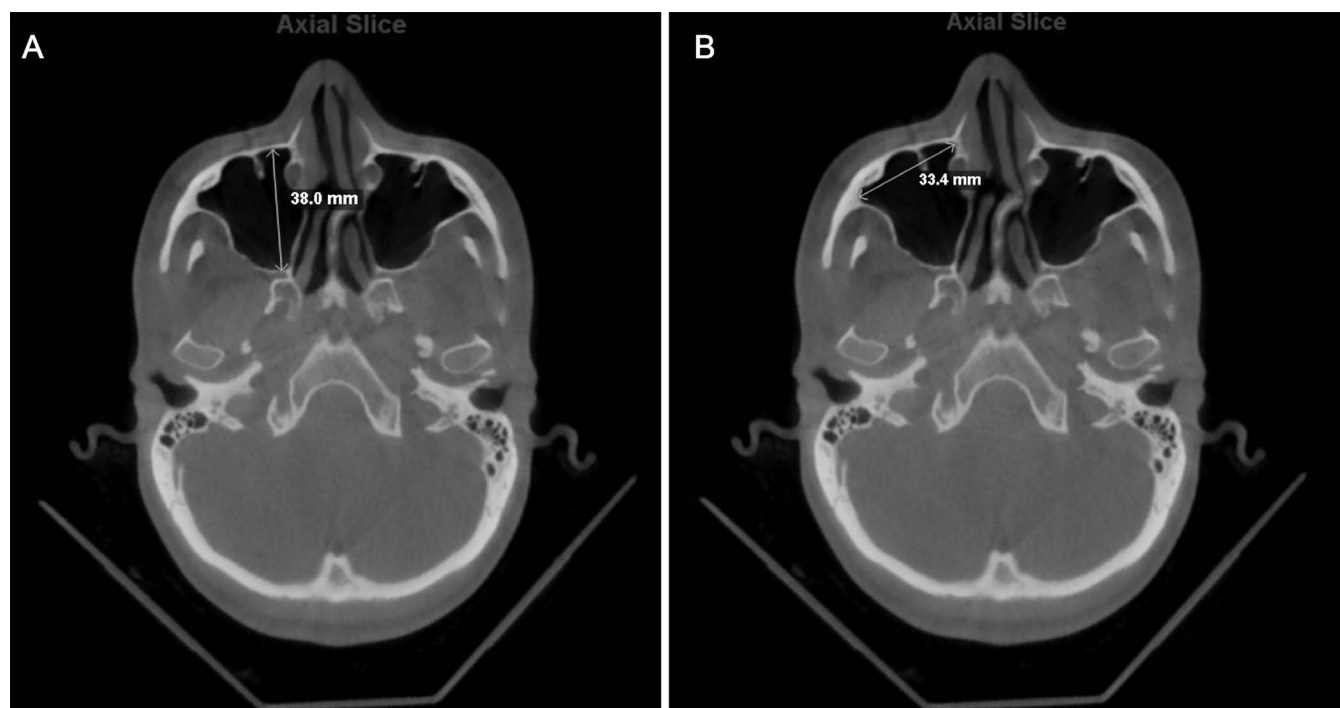


Figure 4. Measurements of maxillary sinus (MS) in axial reconstruction. (A) MS length. (B) MS width.

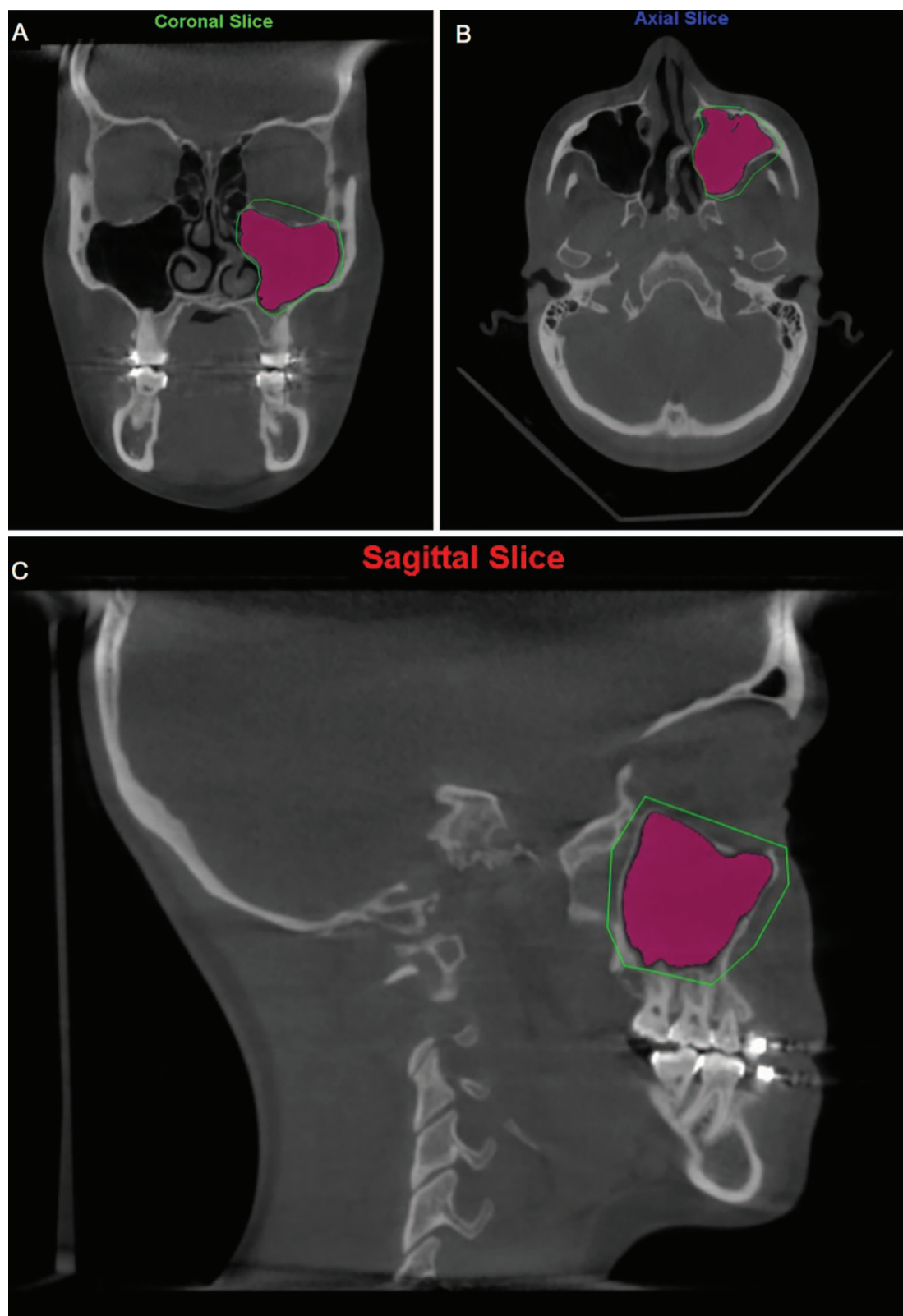


Figure 5. Delimitation of maxillary sinus (MS) volume. (A) Coronal reconstruction. (B) Axial reconstruction. (C) Sagittal reconstruction.

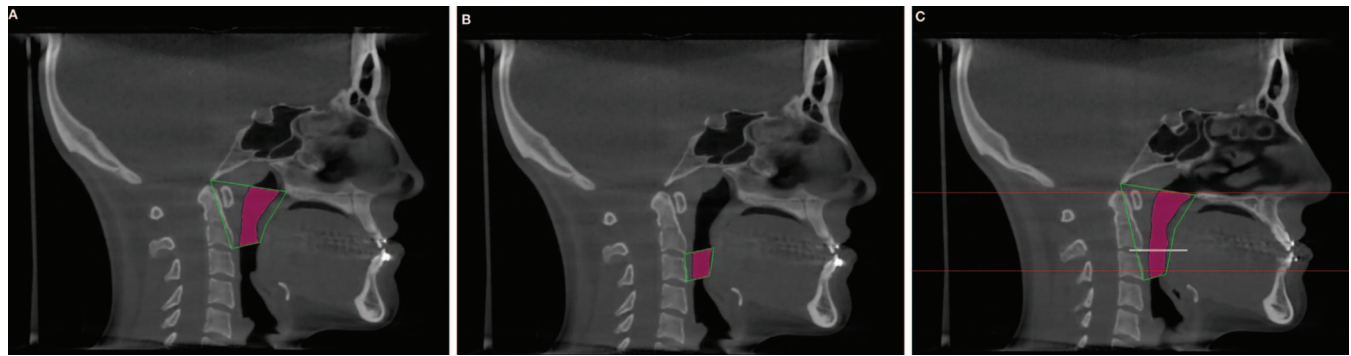


Figure 6. Delimitation of pharyngeal airway space (PAS) volume. (A) Upper PAS. (B) Lower PAS. (C) Total volume and minimum axial area (light grey line).

predictor variables: groups for MS and PAS, CBCT time points for MS and PAS, and sides for MS. All data were analyzed with the R 3.2 for Windows (R Foundation for Statistical Computing, Vienna, Austria) at a 5% significance level ($P < .05$).

RESULTS

Forty-eight patients (16 men and 32 women) were assigned to group 1 (maxillary advancement and mandibular setback) or group 2 (maxillomandibular advancement) with 24 subjects in each group and a mean age of 24.2 ± 6.9 and 28.9 ± 8.8 years, respectively, at the time of surgery.

For both groups, T_0 CBCTs were performed 21.03 ± 18.12 days before surgery, and T_2 CBCTs were acquired at 183.42 ± 69.6 days after surgery. The Kappa test showed excellent intraexaminer (0.92) and interexaminer (0.94) agreement for all measurements and anatomical points assessed. There were no statistically significant differences between sides of MS, so the mixed model was used for statistical analyses.

H-PNS, V-PNS, H-A, and V-A did not significantly affect the variability of the outcome variables of MS and PAS. Therefore, they could not explain it and were not significant to the model. Descriptive analyses with means and standard deviations (SDs) of the horizontal and vertical surgical movements of the maxilla and mandible in both groups are shown in Table 1. In addition, it was observed that there was a large dispersion of these data (Table 1).

Maxillary Sinuses

Variables of MS did not show significant differences in terms of laterality ($P > .05$). Therefore, these variables were not analyzed separately. Table 2 shows the preoperative and postoperative values for all outcome variables of MS in both groups with P values for groups and time points. All variables, in both groups, showed significant postsurgical reductions except for MS length, which showed a significant increase in group 2. All variables showed significant differences between groups (Table 2).

Pharyngeal Airway Space

There was a significant increase in MAA, upper, lower, and total volume of PAS (Table 3). It was observed that the amount of increase in all outcome variables of PAS in group 1 was smaller than in group 2. These variables also showed significant differences between groups (Table 3).

DISCUSSION

The results showed a statistically significant reduction in most measurements of the MS (volume, area, height, width) after surgery in both groups, similar to previous studies.^{2,6,7} Thus, the null hypothesis was rejected. In Le Fort I osteotomy, the maxillary bone is completely separated from the midface. The MS is necessarily included in the osteotomy line.²⁴ In this study, the reduction of the dimensions of MS in the vertical and horizontal directions after bimaxillary

Table 1. Mean and Standard Deviation (SD) of the Measurements of the Surgical Movements (mm) in Both Groups^a

		H-PNS	H-A	H-B	H-Me	V-PNS	V-A	V-B	V-Me
Group 1	Mean	+3.9	+3.6	-3.4	-3.6	-2.5	+3.7	-3.9	-3.7
	SD	2.3	2.8	2.4	2.6	2.2	4.3	2.6	2.9
Group 2	Mean	+2.2	+2.2	+4.4	+3.9	-1.9	-2.3	-3.9	-3.4
	SD	1.8	2.1	3.1	3.8	1.6	2.0	2.7	2.4

^a Horizontal (H) and vertical (V) measures to the cephalometric reference points (PNS, A, B, and Me).

Table 2. Means, Standard Deviations (SDs) and *P* Values of the Measurements of Maxillary Sinus in Both Groups Preoperatively (T_0) and Postoperatively (T_1)

	Group 1		Group 2		<i>P</i> Values	
	T_0 Mean \pm SD	T_1 Mean \pm SD	T_0 Mean \pm SD	T_1 Mean \pm SD	Groups	Time Points
Area (mm ²)	586.92 \pm 162.89	543.01 \pm 149.93	650.79 \pm 164.02	613.18 \pm 180.88	.01*	<.05*
Volume (mm ³)	14160.85 \pm 4480.52	11616.26 \pm 4574.44	17000.83 \pm 6151.49	14345.94 \pm 5669.41	.003*	<.05*
Height (mm)	37.39 \pm 5.89	32.58 \pm 6.67	37.22 \pm 5.03	34.96 \pm 5.80	.04*	<.05*
Width (mm)	35.70 \pm 5.13	34.68 \pm 4.56	37.61 \pm 3.51	37.02 \pm 3.62	.004*	.002*
Length (mm)	28.32 \pm 5.12	27.68 \pm 4.73	31.69 \pm 4.83	32.20 \pm 4.76	.003*	.04*

* *P* < .05.

surgeries could be attributed to bone remodeling. After surgery, a new maxillomandibular relationship was established, and the number of occlusal contacts was increased, favoring the transmission of mechanical stress.²⁵ Nocini et al.⁶ also explained the reduction in MS volume by anterior surgical repositioning of the maxilla, which produced changes in the MS posterior wall. Another reason could be blood accumulation in the MS and inflammatory changes (sinus mucosal thickening, edematous swelling) that occurred after Le Fort I osteotomy, decreasing the MS.⁷

The study also showed that the MS in both groups were within the standards reported by et al.,²⁶ which stated that the expected measures of an anatomically normal MS were 33 mm in height, 23–25 mm in width, and 34 mm in length. Emirzeoglu et al.¹⁸ reported that the volume of MS was 18.0 \pm 6.0 cm³. Luz et al.²⁷ reported similar values of 17.1 \pm 4.8 cm³. In the current study, the postoperative MS volumes were 11.6 \pm 4.5 cm³ and 14.4 \pm 5.6 cm³ for groups 1 and 2, respectively. These values suggested that even with the postsurgical changes, the volume was still within the range reported in previous studies.^{18,27} However, the clinical implications of the decrease in MS volume is still unknown.²

There is no consensus on how segmentation of the PAS should be performed.¹¹ Thus, in this study, PAS was divided into two segments to analyze the effect of each surgical procedure¹⁰ especially on MAA.^{10,28} MAA appears to be relevant since some authors pointed out that there might be a risk of developing obstructive sleep apnea secondary to orthognathic procedures.^{8,11} Previous studies^{8,10,28} demonstrated that maxillary advancement with mandibular setback could increase the total volume of the PAS, in agreement with the findings of this

study. Thus, these results indicated that this type of surgery did not negatively affect the PAS.²⁸ However, other studies reported a decrease in the dimensions of PAS.^{12,29} In group 2, the current study showed a significant increase in the PAS, in agreement with several studies.^{8,10,11,28} The MAA also increased postoperatively in both groups. These results can be helpful and valuable for orthognathic surgery and otolaryngology because these would increase the airway passage and improve breathing, even in patients who underwent maxillary advancement and mandibular setback.

There were statistically significant differences between groups in the MS and PAS, in agreement with Grauer et al.²⁹ and Castro-Silva et al.⁹ They reported that PAS volume could be influenced by the different patterns of malocclusion.^{9,29} In the current study, the preoperative PAS in group 2 was slightly lower than in group 1. However, the postoperative PAS had a greater increase in group 2. In other words, the PAS exhibited relatively similar values after both surgeries.

It is worth mentioning that the sample was very standardized since all CBCT scans were carefully performed by a single radiologist with a standardized scanning protocol. Additionally, the surgical procedures were executed by the same team of experienced surgeons. However, there is still not enough scientific evidence to support the effects of orthognathic surgery in the MS.² Only Panou et al.² conducted a CBCT study evaluating the changes of MS and PAS after orthognathic surgery. Due to the limited sample size, respiratory function was not evaluated in the current study. Thus, future studies are needed to fully discern the impact of orthognathic surgery on morphologic features and correlate these changes with functional alterations.

Table 3. Means, Standard Deviations (SDs) and *P* Values of the Measurements of Pharyngeal Airway Space (PAS) in Both Groups Preoperatively (T_0) and Postoperatively (T_1)

	Group 1		Group 2		<i>P</i> Values	
	T_0 Mean \pm SD	T_1 Mean \pm SD	T_0 Mean \pm SD	T_1 Mean \pm SD	Groups	Time Points
Total volume (mm ³)	16767.49 \pm 5185.73	17238.85 \pm 5346.11	13519.04 \pm 4718.18	16153.66 \pm 4926.31	.009*	.005*
Upper PAS volume (mm ³)	13454.18 \pm 4523.59	13827.15 \pm 4071.76	10942.39 \pm 4109.71	13132.08 \pm 3998.20	.01*	.006*
Lower PAS volume (mm ³)	3336.17 \pm 1458.99	3398.85 \pm 1835.71	2576.65 \pm 1076.38	3021.58 \pm 1508.17	.01*	.01*
Minimum axial area (mm ²)	196.92 \pm 84.86	199.5 \pm 97.62	140.56 \pm 81.18	195.55 \pm 88.42	.003*	.001*

* *P* < .05.

CONCLUSIONS

- Bimaxillary surgery could significantly change the dimensions of MS and PAS.
- Overall, despite MS reduction and PAS increase, the results indicated that the airway was not negatively affected after maxillomandibular advancement or maxillary advancement with mandibular setback.

REFERENCES

1. Dantas WR, Silveira MM, Vasconcelos BC, Porto GG. Evaluation of the nasal shape after orthognathic surgery. *Braz J Otorhinolaryngol*. 2015;81:19–23.
2. Panou E, Motro M, Ates M, Acar A, Erverdi N. Dimensional changes of maxillary sinuses and pharyngeal airway in Class III patients undergoing bimaxillary orthognathic surgery. *Angle Orthod*. 2013;83:824–831.
3. Park JU, Baik SH. Classification of Angle Class III malocclusion and its treatment modalities. *Int J Adult Orthod Orthognath Surg*. 2001;16:19–29.
4. Khajehahmadi S, Rahpeyma A, Hoseini Zarch SH. Association between the lateral wall thickness of the maxillary sinus and the dental status: cone beam computed tomography evaluation. *Iran J Radiol*. 2014;11:e6675.
5. Lorkiewicz-Muszynska D, Kociemba W, Rewekant A, et al. Development of the maxillary sinus from birth to age 18. Postnatal growth pattern. *Int J Pediatr Otorhinolaryngol*. 2015;79:1393–1400.
6. Nocini PF, D'Agostino A, Trevisiol L, Favero V, Pessina M, Procacci P. Is Le Fort I osteotomy associated with maxillary sinusitis? *J Oral Maxillofac Surg*. 2016;74:400.e401–400.e412.
7. Iwamoto M, Watanabe M, Yamamoto M, et al. Prognostic factors for maxillary sinus mucosal thickening following Le Fort I osteotomy: a retrospective analysis. *Maxillofac Plast Reconstr Surg*. 2019;41(1):12.
8. Brunetto DP, Velasco L, Koerich L, Araujo MT. Prediction of 3-dimensional pharyngeal airway changes after orthognathic surgery: a preliminary study. *Am J Orthod Dentofacial Orthop*. 2014;146:299–309.
9. Castro-Silva L, Monnazzi MS, Spin-Neto R, et al. Cone beam evaluation of pharyngeal airway space in Class I, II, and III patients. *Oral Surg Oral Med Oral Pathol Oral Radiol*. 2015;120:679–683.
10. Yamashita AL, Iwaki Filho L, Leite PCC, et al. Three-dimensional analysis of the pharyngeal airway space and hyoid bone position after orthognathic surgery. *J Cranio-maxillofac Surg*. 2017;45:1408–1414.
11. Gokce SM, Gorgulu S, Gokce HS, Bengi AO, Karacayli U, Ors F. Evaluation of pharyngeal airway space changes after bimaxillary orthognathic surgery with a 3-dimensional simulation and modeling program. *Am J Orthod Dentofacial Orthop*. 2014;146:477–492.
12. Al-Moraissi EA, Al-Magaleh SM, Iskandar RA, Al-Hendi EA. Impact on the pharyngeal airway space of different orthognathic procedures for the prognathic mandible. *Int J Oral Maxillofac Surg*. 2015;44:1110–1118.
13. Kochar GD, Chakranarayan A, Kohli S, et al. Effect of surgical mandibular advancement on pharyngeal airway dimensions: a three-dimensional computed tomography study. *Int J Oral Maxillofac Surg*. 2016;45:553–559.
14. Benninger MS, Ferguson BJ, Hadley JA, et al. Adult chronic rhinosinusitis: definitions, diagnosis, epidemiology, and pathophysiology. *Otolaryngology Head Neck Surg*. 2003;129(suppl):S1–S32.
15. Shahidi S, Zamiri B, Momeni Danaei S, Salehi S, Hamedani S. Evaluation of anatomic variations in maxillary sinus with the aid of cone beam computed tomography (CBCT) in a population in South of Iran. *J Dent (Shiraz)*. 2016;17:7–15.
16. von Elm E, Altman DG, Egger M, et al. The Strengthening the Reporting of Observational Studies in Epidemiology (STROBE) statement: guidelines for reporting observational studies. *J Clin Epidemiol*. 2008;61:344–349.
17. Steiner CC. Cephalometrics for you and me. *Am J Orthod*. 1953;39:729–755.
18. Emirzeoglu M, Sahin B, Bilgic S, Celebi M, Uzun A. Volumetric evaluation of the paranasal sinuses in normal subjects using computer tomography images: a stereological study. *Auris Nasus Larynx*. 2007;34:191–195.
19. Kim JH, Park YC, Yu HS, Kim MK, Kang SH, Choi YJ. Accuracy of 3-dimensional virtual surgical simulation combined with digital teeth alignment: a pilot study. *J Oral Maxillofac Surg*. 2017;75:2441.e2441–2441.e2413.
20. Shin JH, Kim MA, Park IY, Park YH. A 2-year follow-up of changes after bimaxillary surgery in patients with mandibular prognathism: 3-dimensional analysis of pharyngeal airway volume and hyoid bone position. *J Oral Maxillofac Surg*. 2015;73:340.e1–340.e9.
21. Bazina M, Cevidanes L, Ruellas A, et al. Precision and reliability of Dolphin 3-dimensional voxel-based superimposition. *Am J Orthod Dentofacial Orthop*. 2018;153:599–606.
22. Masri AA, Yusof A, Hassan R. A three dimensional computed tomography (3D-CT): a study of maxillary sinus in Malays. *Can J Basic Appl Sci*. 2013;1:125–134.
23. Ahmed AG, Gataa IS, Fateh SM, Mohammed GN. CT scan images analysis of maxillary sinus dimensions as a forensic tool for sexual and racial detection in a sample of Kurdish population. *Eur Sci J*. 2015;11(18):1857–7881.
24. Baeg SW, Hong YP, Cho DH, Lee JK, Song SI. Evaluation of sinonasal change after Lefort I osteotomy using cone beam computed tomography images. *J Craniofac Surg*. 2018;29:e34–e41.
25. Preuschoft H, Witte H, Witzel U. Pneumatized spaces, sinuses and spongy bones in the skulls of primates. *Anthropol Anz*. 2002;60:67–79.
26. Karmody CS, Carter B, Vincent ME. Developmental anomalies of the maxillary sinus. *Trans Sect Otolaryngol Am Acad Ophthalmol Otolaryngol*. 1977;84(part 1):723–728.
27. Luz J, Greutmann D, Wiedemeier D, Rostetter C, Rucker M, Stadlinger B. 3D-evaluation of the maxillary sinus in cone-beam computed tomography. *Int J Implant Dent*. 2018;4:17.
28. Souza Pinto GN, Iwaki Filho L, Previdelli ITDS, et al. Three-dimensional alterations in pharyngeal airspace, soft palate, and hyoid bone of Class II and Class III patients submitted to bimaxillary orthognathic surgery: a retrospective study. *J Cranio-maxillofac Surg*. 2019;47(6):883–894.
29. Grauer D, Cevidanes LS, Styner MA, Ackerman JL, Proffit WR. Pharyngeal airway volume and shape from cone-beam computed tomography: relationship to facial morphology. *Am J Orthod Dentofacial Orthop*. 2009;136:805–814.