



Acta Scientiarum. Health Sciences

ISSN: 1679-9291

eduem@uem.br

Universidade Estadual de Maringá
Brasil

Vessoni Iwaki, Lilian Cristina; Iwaki-Filho, Liogi; Mitsunari Takeshita, Wilton; Chicarelli, Mariliani; de Araújo Moreira Preis, Luisa; Bragatto, Fernanda Paula

Solitary bone cyst: an analysis of 12 cases

Acta Scientiarum. Health Sciences, vol. 38, núm. 1, enero-junio, 2016, pp. 103-109

Universidade Estadual de Maringá
Maringá, Brasil

Available in: <http://www.redalyc.org/articulo.oa?id=307245984014>

- How to cite
- Complete issue
- More information about this article
- Journal's homepage in redalyc.org

redalyc.org

Scientific Information System

Network of Scientific Journals from Latin America, the Caribbean, Spain and Portugal

Non-profit academic project, developed under the open access initiative



Solitary bone cyst: an analysis of 12 cases

Lilian Cristina Vessoni Iwaki¹, Liogi Iwaki-Filho¹, Wilton Mitsunari Takeshita^{2*}, Mariliani Chicarelli¹, Luisa de Araújo Moreira Preis¹ and Fernanda Paula Bragatto¹

¹Departamento de Odontologia, Universidade Estadual de Maringá, Maringá, Paraná, Brazil. ²Universidade Federal de Sergipe, Av. Claudio Batista, s/n, 49100-000, Aracaju, Sergipe, Brazil. *Author for correspondence. E-mail: wmtakeshita2@gmail.com

ABSTRACT. To present further information about SBCs based on a retrospective study of 12 cases, by describing their clinical and radiographic characteristics, and comparing them with recent findings. The study examined SBCs from the *Projeto Lesões Bucais* 'treatment and epidemiology of diseases of the oral cavity', run at State University of Maringá, Paraná State, Brazil, between 1995 and 2014. Twelve cases were found among the records of 2.424 patients who had been submitted to different types of biopsy. All cases occurred in the mandible, predominantly in patients in the second decade of life, in the region posterior to canines, and among women. All lesions were solitary, 75% of them unilocular. Helicoidal CT showed expansion and rupture of the cortical bone in one case. Differential diagnosis was confirmed by means of histopathological examination. Treatment consisted of surgical exploration in all cases. Most SBCs are usually asymptomatic and diagnosed by chance on routine X-ray examination. However, SBC can cause bone expansion or bone rupture, only visible with more sophisticated imaging systems. This study showed that the diagnosis of SBC benefits with the use of conventional radiography and CT, associated with careful clinical examinations.

Keywords: bone cysts. spiral computed tomography. cone-beam computed tomography. radiography. diagnosis.

Cisto ósseo solitário: uma análise de 12 casos

RESUMO. Apresentar informações adicionais sobre o COS a partir da revisão de 12 casos, com a descrição das características clínicas e radiográficas, comparando-as com a literatura recente. Realizou-se um estudo retrospectivo observacional de casos de COSs apresentados por pacientes do projeto de extensão: 'Diagnóstico, tratamento e epidemiologia das doenças da cavidade bucal – Lebu', da Universidade Estadual de Maringá – Paraná, Brasil, entre os anos de 1995 e 2014. Dos 2.424 prontuários de pacientes que foram submetidos a diferentes tipos de biópsia, 12 casos de COS foram encontrados e selecionados para pesquisa. Todos os casos ocorreram na mandíbula, preferencialmente em pacientes jovens na segunda década de vida. Ocasionalmente, a expansão da tábua óssea cortical foi notada e, por meio de exame histopatológico, o diagnóstico da lesão foi confirmado. A maioria dos COS são, geralmente, assintomáticos e diagnosticados por acaso em exames radiográficos de rotina. No entanto, o COS pode causar expansão óssea ou rompimento de cortical óssea, visível apenas com métodos de imagem mais sofisticados. O presente trabalho de pesquisa mostrou que o diagnóstico de COS é beneficiado pelo uso da radiografia convencional e tomografia computadorizada, associada a exames clínicos cuidadosos.

Palavras-chave: cistos ósseos. tomografia computadorizada espiral. tomografia computadorizada de feixe cônico. radiografia diagnóstica.

Introduction

Solitary bone cyst (SBC) is a bone lesion without epithelial lining, with intact bony walls, thin connective tissue lining its cavity, can be empty or fluid-filled (serous or blood), and shows no evidence of acute or chronic inflammation (Barnes, Eveson, Reichart, & Sidransky, 2005). Although a variety of terms are used to describe the lesion, such as simple bone cyst, traumatic bone cyst, hemorrhagic bone cyst, idiopathic bone cavity, and bone cyst unicameral (Kyoung & Kwang, 2013; Pushpanshu et al., 2013; Teoh, Watts, Chee, Reid, & Porter, 2010), the World Health

Organization recommends SBC (Barnes et al., 2005). Moreover, the term traumatic bone cyst is considered inadequate given that the incidence of the condition is the same among patients with or without previous trauma (Kuhmichel & Bouloux, 2010).

The SBC is a benign lesion of debatable etiology and pathophysiology (Borgonovo, Tafuro, Censi, Poli, & Maiorana, 2012; Cortell-Ballester, Figueiredo, Berini-Aytés, & Gay-Escoda, 2009; Mathew, Omami, Gianoli, & Lurie, 2012; Mupparapu, Milles, Singer, & Rinaggio, 2008; Nelson, 2010; Teoh et al., 2010), usually located in long bones (Cortell-Ballester et al., 2009; Homem

de Carvalho, Carrard, Martins, Rados, & Filho, 2010; Magremanne, Baeyens, Awada, & Vervae, 2009; Nelson, 2010; Teoh et al., 2010; Velez, Siegel, Mintz, & Rolle, 2010;), as in the upper metaphysis of humerus and femur in children and adolescents (Nelson, 2010). In the head and neck, it affects mainly the posterior region of the mandible (Ferreira Jr., Damante, & Lauris, 2004; Homem de Carvalho et al., 2010; Velez et al., 2010), between the canines and third molars (Kumar, Sherubin, Raman, & Shettar, 2011; Mupparapu et al., 2008), representing one percent of maxillary cysts (Damante, Guerra, & Ferreira Jr., 2002; Harnet et al., 2008; Saia, Fusetti, Emanuelli, Ferronato, & Procopio, 2012).

The incidence of SBC is believed to be higher than the figures reported, since its diagnosed is frequently by chance on conventional radiographies (Homem de Carvalho et al., 2010; Kumar et al., 2011; Magremanne et al., 2009; Nelson, 2010; Suei, Taguchi, & Tanimoto, 2007; Suomalainen, Apajalahti, Kuhlefelt, & Hagstrom, 2009; Strabbing, Gortzak, Vinke, Saridin, & Van Merkesteyn, 2011; Xanthinaki, Choupis, Tosios, Pagkalos, & Papanikolaou, 2006). It is usually asymptomatic (Ferreira Jr. et al., 2004; Harnet et al., 2008; Kumar et al., 2011; Nelson, 2010; Strabbing et al., 2011; Velez et al., 2010; Xanthinaki et al., 2006), unless a secondary infection takes place (Mupparapu et al., 2008), and it rarely causes pain (Mupparapu et al., 2008; Teoh et al., 2010), swelling or loss of function (Teoh et al., 2010). On an x-ray it shows a unilocular or multilocular appearance, is radiolucent and well defined (Ferreira Jr. et al., 2004; Homem de Carvalho et al., 2010; Marx & Stern, 2003; Velez et al., 2010; Strabbing et al., 2011). Scalloping pattern around the roots of adjacent teeth is a typical SBC characteristic (Nelson, 2010; Xanthinaki et al., 2006). Although scalloping is typical in SBC, it is not pathognomonic of the lesion. Root resorption is rare and may cause disappearance of lamina dura in 16-62% of cases (Bhoosreddy, Gadgil, Bhoosreddy, & Velankiwar, 2010). SBCs tend to grow along the axis of the bone, and expansion or erosion of the bone plate are occasionally seen (Damante et al., 2002; Ferreira Jr. et al., 2004; Strabbing et al., 2011; Teoh et al., 2010; Velez et al., 2010), particularly in computed tomography (CT) scans. Two types of CT are frequently used in Dentistry, Cone Beam and helical, the former being more used currently.

The present paper aims to present further information about SBCs based on the review of 12 cases, by describing their clinical and radiographic characteristics, and comparing them with recent findings.

Material and methods

The SBC cases were selected from the project 'Diagnosis, treatment and epidemiology of diseases of the oral cavity (LEBU)', run at State University of Maringá, Paraná State, Brazil, between 1995 and 2014.

Of the total 23.655 records of the project, 2.424 cases had been subject to different types of biopsy, and 12 of them had been diagnosed with SBC—the ones that provided information for this retrospective cohort study. The diagnosis of SBC was based on clinical history, physical examination and laboratory tests. Conventional radiographies were performed in all 12 cases, whereas supplementary CT scans were used in three cases—one helical CT and two Cone Beam CT. All patients had been referred to histopathology.

Inclusion criteria for the lesions were: unitary, no epithelial lining, radiolucent, unilocular or multilocular, located in the mandible, asymptomatic, and teeth showing pulp vitality. The variables investigated were: gender, age, ethnic group, lesion size and location, differential diagnosis, and radiographic characteristics. More emphasis was given to radiographic aspects, which were compared to those of recent studies.

The study's procedures were approved by the Committee for Research Ethics Concerning Human Subjects of the State University of Maringá (Protocol 289/2011).

Data were processed using MINITAB 16 (State College, Pennsylvania, USA), with descriptive analysis expressed as raw data and percentages.

Results

From the 2.424 cases that had been biopsied during the 19 years that the project LEBU had been running, 12 were selected according to the inclusion criteria. However, there were more cases of SBC during this period, which were treated conservatively, with clinical and radiographic examinations, without any specimen sent for histological analysis. On the other hand, histopathologic exams of the 12 cases confirmed the presumptive diagnosis of SBC.

All 12 SBCs were located in the mandible, nine (75%) in the mandibular body, four of them being in the mandibular symphysis and five posterior to the mandibular body, two were in the mandible ramus, and one in the left mandibular condyle, as shown in Table 1.

Age ranged from 13 to 40 years old (mean = 19), ten cases within the second decade of life (83.34%), and two within the fourth decade (16.66%). Four

cases (33.30%) occurred in men, and eight (66.70%) in women.

Table 1. Localization of 12 cases of mandibular SBC.

SBC localization	N	%
Anterior to lower canine	4	33.34
Posterior to lower canine	5	41.66
Mandible ramus	2	16.66
Mandible condyle	1	8.34

Eleven cases (92%) were in Caucasians, and all of them were diagnosed through routine radiographic examination. Panoramic radiographies showed that all cases the radiolucent lesions were well-defined by a radiopaque halo. Five cases (41.66%) showed scalloping around the roots of adjacent teeth (Figure 1A) and in one (8.34%) the margin of the lesion overlapped to that of the teeth (Figure 1B). The remaining 50% of the cases had lesions distant from the teeth. All cases were solitary lesions, nine (75%) were unilocular (Figures 1A and 1B) and three (25%) multilocular, which gave the lesion an appearance of tumour (Figure 1C).

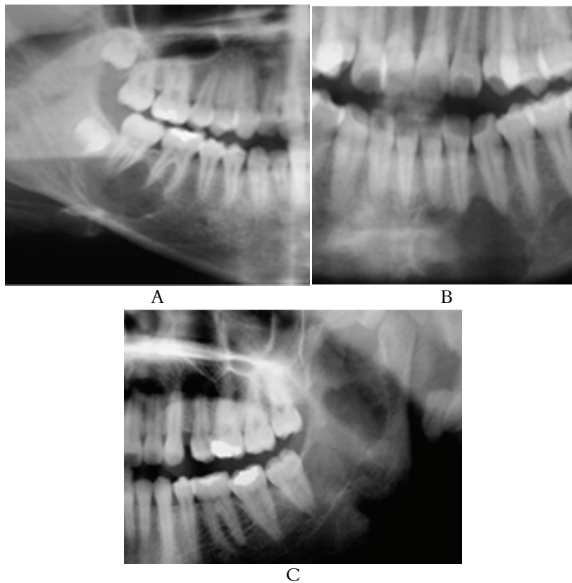


Figure 1. Panoramic radiographies of radiolucent well-defined lesions. A - Unilocular lesion causing scalloping around the lower right molars. B - Unilocular lesion causing scalloping around the incisors and lower left canine. C - Multilocular lesion in the left mandible ramus.

Panoramic radiographies revealed that the maximum diameter of the lesions ranged from 1.5 to 8 cm. In addition, of the three cases that had CT scans performed, Cone Beam scans showed that two (66.67%) cases presented thinning of buccal and lingual cortical bone. The axial and coronal sections of the helical CT showed a radiolucent and distended area in the left condyle, with cortical

thinning, expansion and rupture of its lateral portion (Figures 2A, 2B and 2C).

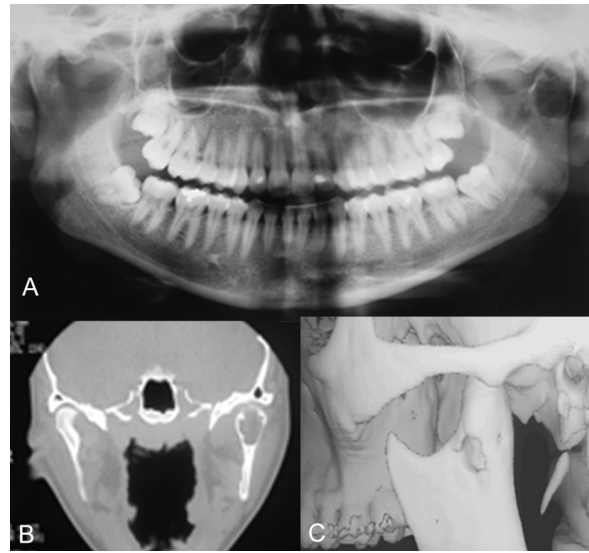


Figure 2. A - Panoramic radiography showing a radiolucent lesion in the left mandible condyle. B - Helical CT (coronal view) showing thinning of buccal and lingual cortical bone in the left condyle. C - Helical CT showing the rupture of the lateral cortex of the left mandible condyle.

Although the images are suggestive of SBC, they are not diagnostic and the lesions could be mistaken for other pathologies. For the multilocular lesion with cortical perforation in the condyle, possible diagnoses were: SBC, aneurysmal bone cyst, central giant cell lesion, intraosseous hemangioma. For the multilocular lesions in the mandible ramus, differential diagnoses of SBC were: ameloblastoma, odontogenic keratocyst, odontogenic myxoma, and central giant cell lesion. For the region posterior to canines two possibilities arised—SBC or odontogenic keratocyst, whereas for the anterior region possible diagnoses were SBC, odontogenic keratocyst, and aneurysmal bone cyst.

For all cases treatment consisted of exploration of the cavity, followed by curettage of bone walls. The surgical exploration confirmed the diagnosis and the cysts disappeared in 100% of the cases. Patients were followed for an average of three years, no recurrence has been reported.

Discussion

The SBC is an uncommon lesion that affects the facial bones and the mandible in particular (Harnet et al., 2008; Homem de Carvalho et al., 2010; Nelson, 2010; Velez et al., 2010). The present study found only 12 cases, confirmed histologically, within the 19 years that the project LEBU had been running. In fact, there were other SBC cases, but

they were treated conservatively, which no need for histopathological analysis.

The diverse classification given to SBC shows its uncertain nature. Its aetiology is speculated by several hypotheses: mechanical trauma, vascular abnormalities, cystic degeneration of bone tumours, ischemic necrosis of bone marrow, changes in calcium metabolism, chronic subclinical changes, changes in osteoclasts functions and in bone remodeling, aberrations of growth and development of bone tissue, hormonal or biochemical changes, abnormal differentiation of mesenchymal cells, hematoma in cavities, or a combination of possibilities (Bhoosreddy et al., 2010; Harnet et al., 2008; Homem de Carvalho et al., 2010; Teoh et al., 2010).

The association between SBC and cemento-osseous dysplasia in the maxilla may be explained by the theory about changes in bone metabolism (Chadwick, Alsufyani, & Lam, 2011; Magliocca, Edwards, & Helman, 2007; Mathew et al., 2012; Mupparapu et al., 2008; Sueti et al., 2007; Velez et al., 2010), given that cemento-osseous dysplasia is characterized by replacement of normal bone with excessive proliferation of fibrous connective tissue. For this reason it is suggested that blockage of interstitial fluid drainage caused by fibro-osseous proliferation may be the cause of SBCs.

Another hypothesis suggests that the intramedullary haemorrhage caused by bone trauma may be followed by failure in the initial organization of the hematoma in the marrow spaces, leading to the formation of traumatic bone cysts (Borgonovo et al., 2012). These cysts may contain blood or serosanguinous fluid, the latter preventing the formation of the hematoma. As the lesion ages, the fluid content tends to reduce, the cavity becomes empty, which enables spontaneous cure of the lesion. However, there is no clear explanation for the early failure in the organization of the hematoma (Mathew et al., 2012). This hypothesis is supported by the fact that these lesions occur mainly in young individuals, in the metaphyses of long bones, and in mandible—areas of frequent trauma. Kuhmichel and Bouloux (2010), however, argues that the incidence of prior trauma in patients with SBC is the same of that in the general population. The most recent hypothesis considers SBCs as synovial cysts originated due to developmental failure, which causes the incorporation of synovial fluid into the bone (Kuhmichel & Bouloux, 2010).

SBC in gnathic bones are essentially restricted to the mandible, although maxillary SBC has been reported. The present study dealt only with

mandibular SBC and found four in the region anterior to canines, five in the region of premolars and molars, two in the angle and the ramus of mandible, as previously found (Kumar et al., 2011; Peñarrocha, Sanchis, Bonet, & Minguez, 2001; Rodrigues & Estrela, 2008; Strabbing et al., 2011; Xanthinaki et al., 2006). Nelson (2010), states that the main location for mandibular SBC is the premolar and molar regions, followed by the mandibular symphysis. The present study found one lesion in the condyle, a rare event, with just over 16 cases reported (Hatakeyma et al., 2012; Kretzschmar, Postma, & Inman, 2005; Kyoung & Kwang, 2013; Magliocca et al., 2007).

Although the SBC can be found at any age (Copete, Kawamata, & Langlais, 1998; Cortell-Ballester et al., 2009; Velez et al., 2010), several authors argue that most cases affect young patients, similarly to the findings of the present study—83.33% of the patients were in their second decade of life, whereas 16.66% in the fourth decade. In Ballester et al. (Cortell-Ballester et al., 2009) study, age ranged between 8 and 45 years old (mean = 26.5), and in Velez et al. (2010) from 9 to 74 years old.

There are conflicting results regarding the prevalence of SBCs among genders. Ballester et al. (Cortell-Ballester et al., 2009) found 14 cases in women and seven in men. Teoh et al. (2010) reported a frequency of 90.62% men and 9.37% women with the lesion. For Homem de Carvalho et al. (2010) the distribution was the same among genders. The present study followed the common 2:1 ratio—eight cases (66.70%) occurred in women and four (33.30%) in men.

Similarly to previous findings, (Velez et al., 2010) SBCs were prevalent among Caucasians in this study—11 out of 12 cases (92%).

There were no radiographic differences between the cases in this study and those from previous findings. SBCs present radiolucent and well defined images (Cortell-Ballester et al., 2009; Kumar et al., 2011; Teoh et al., 2010; Velez et al., 2010;) and may be unilocular or multilocular (Sueti et al., 2007; Velez et al., 2010). An occlusal view shows the radiolucency extending along the bone marrow. Radiographically, the morphology of the lesions was conical, oval, round, and irregular, as in Copete et al. (1998). Scalloping around the adjacent teeth is a common finding in SBCs cases (Bhoosreddy et al., 2010; Cortell-Ballester et al., 2009; Kumar et al., 2011; Nelson, 2010; Velez et al., 2010), though root resorption is rare (Kumar et al., 2011; Borgonovo et al., 2012; Velez et al., 2010). Although the vitality of the dental pulp is rarely affected (Magremanne et al., 2009; Velez et al., 2010), response to vitality

testing can be temporarily reduced due to the expansion of the lesion and increased pressure around the roots (Hatakeyma et al., 2012). In this study, five patients (55.56%) showed interradicular scalloping, while Copete et al. (1998) found that 30 out of the 44 cases (68%) showed the same pattern. In addition, no root resorption was observed and 100% of the cases showed dental vitality.

Although of rare occurrence, the SBC can cause expansion or thinning of the cortical bone (Ferreira Jr. et al., 2004; Mathew et al., 2012; Strabbing et al., 2011; Velez et al., 2010). A CT scan can confirm the phenomenon and show whether the cavity is empty or fluid-filled, which helps the differential diagnosis (Hatakeyma et al., 2012). Because conventional x-rays are not able to show expansion of the cortical bone, it was believed that SBCs did not cause it. However, with the advent of CT scans, particularly the Cone Beam CT, it is possible to verify the phenomenon in a considerable number of cases. The thinning of the cortical bone is an important incidence to look for, so that its rupture can be prevented and a more conservative approach can take place, such as the spontaneous recovery of the lesion (Damante et al., 2002). In the present study, there was one case with expansion and rupture of the cortical bone around the mandible condyle. Mathew et al. (2012) performed an axial section of Cone Beam CT of SBC in the ramus and posterior body of the mandible and showed considerable expansion of the buccal cortex.

Successful treatment of SBC depends on its correct diagnosis, given that it can be mistaken by several other lesions, such as ameloblastoma, central giant cell lesion, florid cemento-osseous dysplasia (Chadwick et al., 2011), odontogenic myxoma (Velez et al., 2010), aneurysmal bone cyst, odontogenic keratocyst (Magliocca et al., 2007). Correct diagnosis, in turn, is dependant on excisional biopsy and histopathology (Homem de Carvalho et al., 2010; Kretzschmar et al., 2005).

Xanthinaki et al. (2006), state that the ultimate diagnosis of SBC happens during surgery, at the moment that an empty cavity without epithelial lining is observed. The cyst wall is then carefully curetted in order not to damage the roots or the inferior alveolar nerve. As this surgical exploration causes bleeding, a blood clot is formed and, consequently, bone healing is stimulated. Spontaneous regression of SBCs is possible, with no need for surgical intervention (Magremanne et al., 2009; Saito et al., 1992). A 1- to 7-year follow-up study (Kumar et al., 2011) of ten cases of presumptive diagnosis of SBC showed that all patients remained asymptomatic throughout the

period. One lesion was considered static, two increased in size, six were remodelled, and one underwent complete regression. The authors (Damante et al., 2002) argue that clinical and radiographic follow-up is a viable and alternative option, with no need for invasive procedures.

For non-surgical treatment of SBC, anamnesis and intraoral examination are essential, given that on palpation the cortical bone is usually intact and the condition is asymptomatic. This is different for ameloblastoma, odontogenic myxoma or central giant cell lesion—most likely they show cortical rupture and are sensitive to palpation. Differential diagnosis of cystic lesions, particularly between SBC and odontogenic keratocyst, lies in radiolucency—the former is less radiolucent than the latter. If any doubt remains, biopsy is recommended.

Borgonovo et al. (2012) suggest that paediatric surgery should be minimally invasive, with careful clinical and radiographic evaluation before planning the intervention. Radiographic control is recommended for highly suggestive cases in very cooperative patients, who can attend to periodic appointments. If the lesion was diagnosed in an early stage of development, radiographic control may reveal its growth. The maintenance of a conservative treatment will, again, depend on anamnesis and intraoral examination, which should show that the condition has not changed clinically. Subsequent x-rays should show that the lesion's growth has stabilised and is progressively losing its margins and its radiolucency. The present study had SBC cases treated surgically only, the method whose diagnosis is definite.

Although recurrence of SBC is uncommon, it has been reported (Baqain, Jayakrishnan, Farthing, & Hardee, 2005). This is why Suei et al. (2007) suggest that periodic postoperative observation should be performed, for a minimum period of three years, until bone healing is complete and confirmed radiographically.

Conclusion

The prevalence of SBC may be higher than that reported, given that in most cases the lesion is asymptomatic and its diagnosis occurs by chance on conventional x-rays. Helical CT revealed expansion and rupture of the cortical bone in the condyle, information that could not be observed with conventional radiography. Thus, these results demonstrate the importance of the association of CT with careful clinical examinations and conventional x-rays in the diagnosis of SBC.

References

- Baqain, Z. H., Jayakrishnan, A., Farthing, P. M., & Hardec, P. (2005). Recurrence of a solitary bone cyst of the mandible: case report. *British Journal of Maxillofacial Surgery*, 43(4), 333-335.
- Barnes, L., Eveson, J. W., Reichart, P., & Sidransky, D. (2005). *World health organization classification of tumours. Pathology and Genetics of Head and Neck Tumours*. Lyon, FR: IARC Press.
- Bhoosreddy, A. R., Gadgil, R. M., Bhoosreddy, S. A., & Velankiwar, G. N. (2010). Solitary bone cyst: a case report and review of literature. *Journal of Indian Academy of Oral Medicine and Radiology*, 22(1), 27-29.
- Borgonovo, A. E., Tafuro, C. M., Censi, R., Poli, P., & Maiorana, C. (2012). Minimally invasive surgical approach in a large mandibular solitary cyst: case report and review of the literature. *Minerva Stomatologica*, 61(5), 239-245.
- Chadwick, J. W., Alsufyani, N. A., & Lam, E. W. (2011). Clinical and radiographic features of solitary and cemento-osseous dysplasia-associated simple bone cysts. *Dentomaxillofacial Radiology*, 40(4), 230-235.
- Copete, M. A., Kawamata, A., & Langlais, R. P. (1998). Solitary bone cyst of the jaws: radiographic review of 44 cases. *Oral Surgery, Oral Medicine, Oral Pathology, Oral Radiology and Endodontology*, 85(2), 221-225.
- Cortell-Ballester, I., Figueiredo, R., Berini-Aytés, L., & Gay-Escoda, C. (2009). Traumatic bone cyst: a retrospective study of 21 cases. *Medicina Oral, Patología Oral y Cirugía Bucal*, 14(5), 239-243.
- Damante, J. H., Guerra, E. N., & Ferreira Jr., O. (2002). Spontaneous resolution of simple bone cysts. *Dentomaxillofacial Radiology*, 31(3), 182-186.
- Ferreira Jr., O., Damante, J. H., & Lauris, J. R. (2004). Simple bone cyst versus odontogenic keratocyst: differential diagnosis by digitized panoramic radiography. *Dentomaxillofacial Radiology*, 33(6), 373-378.
- Harnet, J. C., Lombardi, T., Klewansky, P., Rieger, J., Tempe, M. H., & Clavert, J. M. (2008). Solitary bone cyst of the jaws: a review of the etiopathogenic hypotheses. *Journal of Oral and Maxillofacial Surgery*, 66(11), 2345-2348.
- Hatakeyma, D., Tamaoki, N., Lida, K., Yonemoto, K., Kato, K., Makita, H., ... Shibata, T. (2012). Simple bone cyst of the mandibular condyle in a child: report of a case. *Journal of Oral and Maxillofacial Surgery*, 70(9), 2118-2123.
- Homem de Carvalho, A. L., Carrard, V. C., Martins, M. D., Rados, P. V., & Filho, M. S. (2010). Simple bone cyst: report of cases and proposal for a minimal surgical intervention. *International Journal of Pediatric Otorhinolaryngology*, 74(12), p.1449-1451.
- Kretschmar, D. P., Postma, G. N., & Inman, J. L. (2005). Intraoral endoscopic enucleation of a central mandibular condylar lesion. *Journal of Oral and Maxillofacial Surgery*, 63(6), 865-869.
- Kuhmichel, A., & Bouloux, G. F. (2010). Multifocal traumatic bone cysts: case report and current thoughts on etiology. *Journal of Oral and Maxillofacial Surgery*, 68(1), 208-812.
- Kumar, N. D., Sherubin, J. E., Raman, U., & Shettar, S. (2011). Solitary bone cyst. *Indian Journal of Dental Research*, 22(1), 172-174.
- Kyoung, A. K., & Kwang, J. K. (2013). Recurrent simple bone cyst of the mandibular condyle: a case report. *Imaging Science in Dentistry*, 43(1), 49-53.
- Magliocca, K. R., Edwards, S. P., & Helman, J. I. (2007). Traumatic bone cyst of the condylar region: report of 2 cases. *Journal of Oral Maxillofacial Surgery*, 65(6), 1247-1250.
- Magremanne, M., Baeyens, W., Awada, S., & Vervaeck, C. (2009). Kyste osseux solitaire de la mandibule et fibrine riche en plaquettes (PRF). *Revue de Stomatologie et de Chirurgie Maxillofaciale*, 110(2), 105-108.
- Marx, R. E., & Stern, D. (2003). Conditions of developmental disturbances. In L. C. Bywaters (Ed.). (2003). *Oral and maxillofacial pathology: a rationale for diagnosis and treatment* (p. 211-213). Illinois, IL: Quintessence Publishing.
- Mathew, R., Omami, G., Gianoli, D., & Lurie, A. (2012). Unusual cone-beam computerized tomography presentation of traumatic (simple) bone cyst: case report and radiographic analysis. *Oral Surgery, Oral Medicine, Oral Pathology, Oral Radiology and Endodontology*, 113(3), 410-413.
- Mupparapu, M., Milles, M., Singer, S. R., & Rinaggio, J. (2008). Rare, simultaneous, multiple, and recurrent mandibular bone cysts. *Quintessence International*, 39(4), 331-336.
- Nelson, B. L. (2010). Solitary bone cyst. *Head Neck Pathol*, 4(3), 208-209.
- Peñarrocha, M. D., Sanchis, J. M. B., Bonet, J. M., & Minguez, J. M. S. (2001). Surgical treatment and follow-up of solitary bone cyst of the mandible: a report of seven cases. *British Journal of Oral and Maxillofacial Surgery*, 39(3), 221-223.
- Pushpanshu, K., Kaushik, R., Punyani, S. R., Jasuja, V., Raj, V., & Seshadri, A. (2013). Concurrent central odontogenic fibroma (WHO Type) and traumatic bone cyst: report of a rare case. *Quantitative Imaging in Medicine and Surgery*, 3(6), 341-346.
- Rodrigues, C. D., & Estrela, C. (2008). Traumatic bone cyst suggestive of large apical periodontitis. *Journal of Endodontics*, 34(4), 484-489.
- Saia, G., Fusetti, S., Emanuelli, E., Ferronato, G., & Procopio, O. (2012). Intraoral endoscopic enucleation of a solitary bone cyst of the mandibular condyle. *International Journal of Oral and Maxillofacial Surgery*, 41(3), 317-320.
- Saito, Y., Hoshina, Y., Nagamine, T., Nakajima, T., Suzuki, M., & Hayashi, T. (1992). Simple bone cyst. A clinical and histopathologic study of fifteen cases. *Oral Surgery, Oral Medicine, Oral Pathology*, 74(4), 487-491.
- Strabbing, E. M., Gortzak, R. A., Vinke, J. G., Saridin, C. P., & Van Merkesteyn, J. P. (2011). An atypical presentation of a solitary bone cyst of the mandibular

- ramus: a case report. *Journal of Craniomaxillofacial Surgery*, 39(2), 45-47.
- Suomalainen, A., Apajalahti, S., Kuhlefelt, M., & Hagstrom, J. (2009). Simple bone cyst: a radiological dilemma. *Dentomaxillofacial Radiology*, 38(3), 174-177.
- Suei, Y., Taguchi, A., & Tanimoto, K. (2007). Simple bone cyst of the jaws: evaluation of treatment outcome by review of 132 cases. *Journal Oral Maxillofacial Surgery*, 65(5), 918-923.
- Teoh, K. H., Watts, A. C., Chee, Y. H., Reid, R., & Porter, D. E. (2010). Predictive factors for recurrence of simple bone cyst of the proximal humerus. *Journal of Orthopaedic Surgery*, 18(2), 215-219.
- Velez, I., Siegel, M. A., Mintz, S. M., & Rolle, R. (2010). The relationship between idiopathic bone cavity and orthodontic tooth movement: analysis of 44 cases. *Dentomaxillofacial Radiology*, 39(3), 162-166.
- Xanthinaki, A. A., Choupis, K. I., Tosios, K., Pagkalos, V. A., & Papanikolaou, S. I. (2006). Traumatic bone cyst of the mandible of possible iatrogenic origin: a case report and brief review of the literature. *Head & Face Medicine*, 2(1), 40.

Received on June 27, 2014.

Accepted on December 3, 2015.

License information: This is an open-access article distributed under the terms of the Creative Commons Attribution License, which permits unrestricted use, distribution, and reproduction in any medium, provided the original work is properly cited.