



Acta Scientiarum. Health Sciences

ISSN: 1679-9291

eduem@uem.br

Universidade Estadual de Maringá
Brasil

Yamashita, Amanda Lury; Iwaki Filho, Liogi; Chicarelli da Silva, Mariliani; Mitsunari
Takeshita, Wilton; Vessoni Iwaki, Lilian Cristina
Effect of orthognathic surgery on pharyngeal airway space: a cephalometric evaluation
using Dolphin Imaging software
Acta Scientiarum. Health Sciences, vol. 37, núm. 2, julio-diciembre, 2015, pp. 205-209
Universidade Estadual de Maringá
Maringá, Brasil

Available in: <http://www.redalyc.org/articulo.oa?id=307242823014>

- How to cite
- Complete issue
- More information about this article
- Journal's homepage in redalyc.org

redalyc.org

Scientific Information System

Network of Scientific Journals from Latin America, the Caribbean, Spain and Portugal

Non-profit academic project, developed under the open access initiative



Effect of orthognathic surgery on pharyngeal airway space: a cephalometric evaluation using Dolphin Imaging software

Amanda Lury Yamashita¹, Liogi Iwaki Filho¹, Mariliani Chicarelli da Silva¹, Wilton Mitsunari Takeshita² and Lilian Cristina Vessoni Iwaki^{1*}

¹Departamento de Odontologia, Universidade Estadual de Maringá, Av. Colombo, 5790, 87020-900, Maringá, Paraná, Brazil. ²Universidade Federal de Sergipe, Aracajú, Sergipe, Brazil. *Author for correspondence. E-mail: lilianiwaki@gmail.com

ABSTRACT. Orthognathic surgery is widely used in the treatment of dento-maxillofacial deformities, which changes both the facial appearance and the pharyngeal airway space. The aim of this study was to evaluate cephalometric changes in the pharyngeal airway space before and after orthognathic surgery in patients with Class II and Class III malocclusions. The sample consisted of 38 lateral cephalograms, 17 of patients with Class II who had undergone mandibular advancement, and 21 of patients with Class III who had undergone mandibular setback. Cephalometric analysis of Arnett-Gunson FAB Surgery using Dolphin Imaging 11.5 evaluated point B' and Pog'. Statistical analysis used Paired t-test at 5% significance level. The increase in the means of point B' and Pog' after mandibular advancement was not statistical. Similarly, the means of point B' and Pog' did not differ after mandibular setback. Thus, the pharyngeal airway space at the level of B' and Pog' kept constant pre and post orthognathic surgery for both Class II and Class III.

Keywords: oral surgical procedures, malocclusion, mandibular osteotomy, mandibular advancement, pharynx, diagnostic imaging.

Avaliação cefalométrica do espaço aéreo faríngeo após cirurgia ortognática por meio do software *Dolphin Imaging*

RESUMO. A cirurgia ortognática é amplamente utilizada no tratamento de deformidades dento-maxilo-faciais, alterando a aparência facial e o espaço aéreo faríngeo. O objetivo deste estudo foi analisar a variação cefalométrica do espaço aéreo faríngeo antes e após a cirurgia ortognática. Foram analisadas 38 radiografias cefalométricas laterais, 17 de pacientes com Classe II submetidos ao avanço mandibular e 21 de pacientes com Classe III submetidos ao recuo mandibular. O espaço aéreo faríngeo foi analisado por meio do *software Dolphin Imaging 11.5* utilizando a análise de Arnett-Gunson FAB Surgery, observando os pontos B' e Pog'. Os dados foram analisados com o Teste t para Amostras Pareadas com nível de significância de 5%. O aumento da média dos pontos B' e Pog' após o avanço mandibular não foi estatisticamente significante. Para a cirurgia de recuo mandibular, as médias dos pontos B' e Pog' mantiveram-se estáveis. Assim, o espaço aéreo faríngeo em nível dos pontos B' e Pog' mantiveram-se constantes antes e após a cirurgia ortognática para Classe II e Classe III.

Palavras-chave: Procedimentos de cirurgia oral, má oclusão, osteotomia mandibular, avanço mandibular, farínge. diagnóstico por imagem.

Introduction

Dento-maxillofacial deformities can cause changes in the volume of the pharyngeal airway space (PAS), as well as breathing problems if the PAS is reduced enough to result in blockage of air passage. In turn, this obstruction may result in 'obstructive sleep apnea-hypopnea syndrome' (GOKCE et al., 2012).

Treatment of Class II and III malocclusions involves a multidisciplinary approach and depends on the severity of the deformities. With regard to Dentistry, facial deformities of mild nature could be treated orthodontically, whilst more severe cases,

those affected aesthetically and functionally, may require a combination of orthodontics and orthognathic surgery (GOKCE et al., 2012).

Orthognathic surgery has proved effective as treatment for patients with dento-maxillofacial deformities. Class II treated with mandibular advancement can unblock the pharynx, as there is an increase of the PAS (GOODDAY, 2009). On the other hand, mandibular setback as treatment for Class III can reduce the PAS, given that the ligaments and muscles of the tongue are connected to the hyoid bone and the mandible. Thus, when the mandible is posteriorly repositioned, the tongue

assumes a more posterior position, narrowing the PAS. (SAITOH, 2004; CHEN et al., 2005; KITAGAWARA et al., 2008; MUTO et al., 2008). This is why one of the challenges in the planning of orthognathic surgery is to balance concerns related to facial esthetics and changes in the PAS (CONLEY; BOYD, 2007)

Obstruction of the PAS can be detected through imaging methods such as lateral cephalometric radiographs and computed tomography, though the former is still the most used method (JOHNS et al., 1998). Lateral cephalometry enables analysis of the pharynx, the soft palate, the tongue, and the hyoid bone, with their soft and bony structures (JOHNS et al., 1998; TSELNIK; POGREL, 2000; LIUKKONEN et al., 2002; MARSAN et al., 2008).

The purpose of this study was to evaluate cephalometric changes, using Dolphin Imaging software, in the PAS at the level of soft tissue B point (point B') and soft tissue pogoniu (Pog') in patients who underwent orthognathic surgery to correct Angle Class II and Class III dentofacial deformities.

Material and methods

The study was approved by the Standing Committee on Ethics in Human Research of the State University of Maringá (Protocol 16804). The records of 38 patients were analyzed—19 women and 19 men, mean age of 28.5 years old, average weight and height for their age. They were all diagnosed with skeletal deformities—17 with Class II and 21 with Class III. They were selected from the medical records of the Project "Orthognathic Surgery Clinic of the State University of Maringá", and had undergone orthognathic surgery between 2008 and 2012.

Inclusion criteria were adult patients with skeletal Classes II or III deformities treated surgically, who had pre and postoperative lateral cephalograms. The radiographs should have been taken within the same standards—with patients positioned in the cephalostat, the midsagittal plane perpendicular to the ground, the Frankfurt horizontal plane parallel to the ground, the film perpendicular to the ground, 1.52 m focus-film distance, and the central X-ray beam aligned to the center of the loaded cassette. Exclusion criteria were tonsillectomy, adenoidectomy, genioplasty, other surgeries for chronic diseases of the upper airways, and excessive obesity.

Both pre and postoperative lateral cephalograms were taken with the same equipment and parameters: Orthoralix 9200 GENDEX (Dentsply®,

Des Plainnes, USA), cephalostat regulated at 70 kVp, 10 mA, 1.2 seconds exposure time, Kodak T-Mat G/RA films (18 x 24 cm, Carestream Health®, New York, USA), with their metallic cassette and intensifying screen (Kodak Lanex Medium Extraoral Imaging Screens X-Omat). The cephalograms were digitized using a scanner and a transparency adaptor (HP Scanjet G4050, Hewlett-Packard Company®, Washington, USA) at 300 dpi resolution and archived in TIFF format. Adobe Photoshop® 7.0 (Adobe Systems Incorporated, San Jose, California) was used to improve brightness, contrast and sharpness. The cephalograms were analyzed according to the type of dentofacial deformity: Class II for patients who had undergone mandibular advancement and Class III for patients who had undergone mandibular setback.

Cephalometric analysis of Arnett-Gunson FAB Surgery was performed by a single examiner using Dolphin Imaging 11.5 software (Figure 1A and 1B) assessing point B' and Pog'. Statistical analysis between pre and postoperative cephalograms consisted of Paired t-test at 5% significance level, using IBM SPSS 21.0 (Armonk, NY: IBM Corp.).

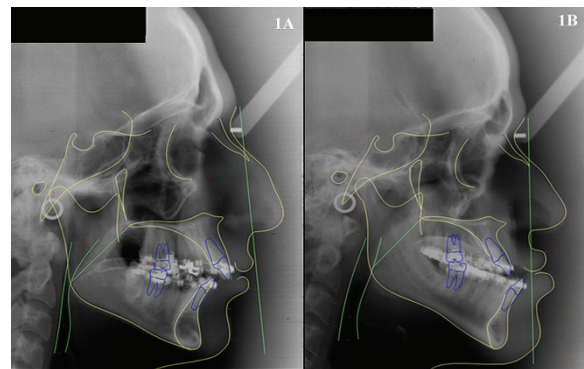


Figure 1. Cephalometric analysis using Dolphin Imaging 11.5 software: 1A. Class II. 1B. Class III.

Results and discussion

Table 1 displays pre and postoperative means and standard deviations, in mm, of point B' and Pog' of the 17 cases of Class II and the 21 cases of Class III.

Table 1. Pre and postoperative means and standard deviations (M ± SD) of the pharyngeal airway space (PAS) at the level of point B' and Pog' for Class II and Class III.

Malocclusion	PAS level	Surgical period		P-values
		Preoperative	Postoperative	
Class II (n = 17)	B'	37.94 ± 19.39	43.44 ± 24.66	p = 0.176
	Pog'	48.00 ± 21.58	53.61 ± 27.77	p = 0.226
Class III (n = 21)	B'	35.17 ± 24.67	34.86 ± 26.45	p = 0.911
	Pog'	41.01 ± 28.05	41.81 ± 29.85	p = 0.745

For Class II (Figure 2), the means of the PAS after orthognathic surgery increased 14.50% for

point B' and 11.69% for Pog', though these increments were not statistical.

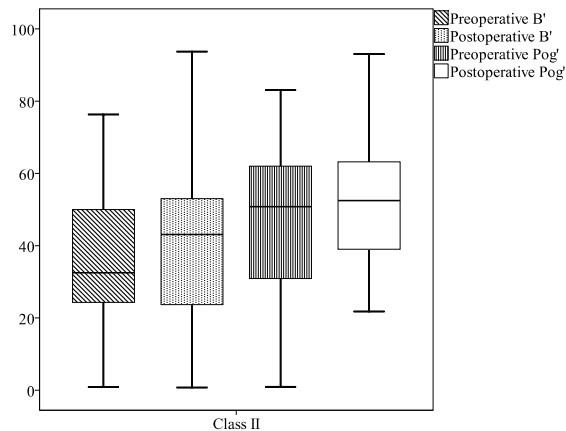


Figure 2. Pre and postoperative values of pharyngeal airway space at the level of point B' and Pog' for the 17 cases of Class II.

The means of PAS for Class III (Figure 3) reduced 0.88% for point B' and increased 1.95% for Pog', although, again, there was no significant differences before and after surgery.

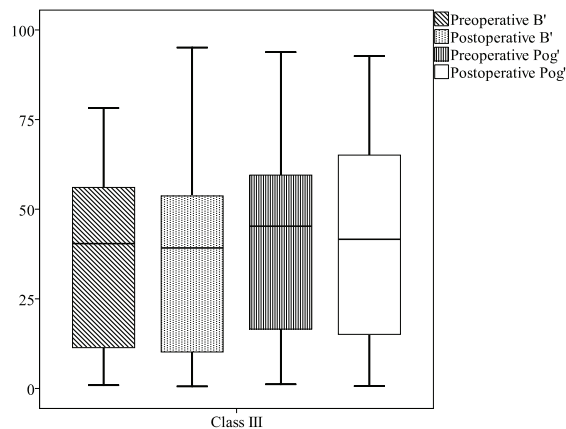


Figure 3. Pre and postoperative values of pharyngeal airway space at the level of point B' and Pog' for the 21 cases of Class III.

The relationship between breathing problems and craniofacial morphology, particularly the relationship between the anatomy of the PAS and the effects of orthognathic surgery, have been examined by several studies (CEYLAN; OKTAY, 1995; EGGENSPERGER et al., 2005), mainly due to changes and consequences caused by different treatments.

According to Gokce et al. (2012), in order to select patients for orthognathic surgery, it is important that the growth of anatomical structures, particularly of the PAS, is complete by the time of the surgery. This would ensure one can evaluate morphological changes caused by the intervention.

In the present study, the patients' mean age was 28.5 years, hence with established growth.

Lateral cephalometry is still a widely used imaging tool to examine the PAS of patients who underwent orthognathic surgery (HOCHBAN et al., 1996; GU et al., 2000; TSELNIK; POGREL, 2000; LIUKKONEN et al., 2002). Cephalograms allow the visualization of the structures and abnormalities of soft and hard tissues (JOHNS et al., 1998; BECKER et al., 2012), they are of low cost, require minimal radiation exposure, are easy to perform (BATTAGEL et al., 2000; PRADO et al., 2012), and can be associated to other exams (JOHNS et al., 1998; TSELNIK; POGREL, 2000; LIUKKONEN et al., 2002; MARSAN et al., 2008; MUTO et al., 2008). On the other hand, they show two-dimensional images of three-dimensional structures (CEYLAN; OKTAY, 1995; BATTAGEL; L'ESTRANGE, 1996; JACOBSON, 2007), are performed with patients awake and not in the supine position.

There is an important relationship between lateral cephalometry, as a measure of PAS, and computed tomography, as a measure of volume (MARSAN et al., 2009), mainly because cephalometric analysis is considered an appropriate method to examine changes in the position of the face bones and their consequences on the PAS (CEYLAN; OKTAY, 1995; BATTAGEL; L'ESTRANGE, 1996; HOCHBAN et al., 1996; JOHNS et al., 1998; GU et al. 2000; TSELNIK; POGREL, 2000; JOHAL; CONAGHAN, 2004; LAM et al., 2004; SAITOH, 2004; CHEN et al., 2005). It was due to this relationship that the present study used cephalometric analysis, which showed no statistical differences in the PAS for both classes.

Although the means of the PAS at the level of point B' and Pog' increased after surgery for Class II, the differences were not statistical, unlike previous studies that found significant increase in the PAS after surgery (PEREIRA-FILHO et al., 2011; PRADO et al., 2012).

The amount of jaw advancement also changes the airway space. Little change in the retropalatal and retrolingual dimensions might happen due to small mandibular advancement (MEHRA et al., 2001). Conversely, major mandibular advancement may lead to significant increase in the PAS. Such variations may explain the differences between the results of previous studies and those of the present one.

However, as Prado et al. (2012) assert, it is important to bear in mind that changes in the PAS are not necessarily permanent, as research on the matter is debatable and controversial. Whereas some

longitudinal studies show an increase in the PAS after maxillomandibular advancement (TURNBULL; BATTAGEL, 2000; MEHRA et al., 2001), others show reduction in the dimensions after surgery (FROST; 2000).

Similar to previous research (KITAGAWARA et al., 2008, PEREIRA-FILHO et al., 2011), mandibular setback for Class III did not affect the PAS in the present study. However, some studies show that major mandibular setback can cause narrowing of the upper airway space (HOCHBAN et al., 1996; GU et al., 2000; TSELNIK, POGREL, 2000; LIUKKONEN et al., 2002; SAITOH, 2004; EGGENSBERGER et al., 2005; MUTO et al., 2008; MARSAN et al., 2008) due to changes in the position of the hyoid bone (GU et al., 2000) and of the tongue (HOCHBAN et al., 1996), and increase in the length and the slope of the soft palate (GOKCE et al., 2012).

In this study, cephalometric analysis of Arnett-Gunson FAB Surgery used Dolphin Imaging 11.5, considered an accurate program by some authors (GOSSETT et al., 2005; PEREIRA-FILHO et al., 2011). However, errors were found with the use of Dolphin Imaging 8.0, errors that could result in clinically significant miscalculations (POWER et al., 2005).

A limitation of the present study is that, within the orthognathic surgery for each malocclusion, the type of surgery were not specified and taken into account. According to Aydemir et al. (2012), different surgical procedures have different impact on the PAS, which may explain the difference between the present study and previous research. In addition, the reduced number of specimens in both samples of the present study may also explain the divergent results compared to previous research.

Despite the growing body of research on the subject, it is difficult to compare studies due to the diversity of methods. Thus, the impact of orthognathic surgery on the PAS needs further investigation, perhaps using different types of imaging methods. In the present study three-dimensional structures were evaluated using lateral cephalograms, a two dimensional imaging method. However, with the increasing popularity of cone beam computed tomography, due to its low radiation exposure and continuous development, perhaps it becomes a routine method for evaluating the PAS in near future, providing researchers more information on the structures.

Conclusion

Cephalometric analyses of the PAS using Dolphin Imaging 11.5 in patients who underwent

orthognathic surgery to correct Class II and Class III dentofacial deformities found no statistical difference at the level of point B' and Pog' before and after surgery, for both classes.

References

- AYDEMIR, H.; MEMIKOGLU, U.; KARASU, H. Pharyngeal airway space, hyoid bone position and head posture after orthognathic surgery in class III patients. **The Angle Orthodontist**, v. 82, n. 6, p. 993-1000, 2012.
- BATTAGEL, J. M.; JOHAL, A.; KOTECHEA, B. A cephalometric comparison of subjects with snoring and obstructive sleep apnoea. **European Journal of Orthodontics**, v. 22, n. 4, p. 353-365, 2000.
- BATTAGEL, J. M.; L'ESTRANGE, P. R. The cephalometric morphology of patients with obstructive sleep apnoea (OSA). **European Journal of Orthodontics**, v. 18, n. 6, p. 557-569, 1996.
- BECKER, O. E.; AVELAR, R. L.; GÖELZER, J. G.; DOLZAN, ADO. N.; HAAS, O. L. JR.; DE OLIVEIRA, R. B. Pharyngeal airway changes in Class III patients treated with double jaw orthognathic surgery-maxillary advancement and mandibular setback. **Journal of Oral and Maxillofacial Surgery**, v. 70, n. 11, p. 639-647, 2012.
- CEYLAN, I.; OKTAY, H. A study on the pharyngeal size in different skeletal patterns. **American Journal of Orthodontics and Dentofacial Orthopedics**, v. 108, n. 1, p. 69-75, 1995.
- CHEN, F.; TERADA, K.; HANADA, K.; SAITO, I. Predicting the pharyngeal airway space after mandibular setback surgery. **Journal of Oral and Maxillofacial Surgery**, v. 63, n. 10, p. 1509-1514, 2005.
- CONLEY, S. R.; BOYD, S. B. Facial soft tissue changes following maxillo-mandibular advancement for treatment of obstructive sleep apnea. **Journal of Oral and Maxillofacial Surgery**, v. 65, n. 7, p. 1332-1340, 2007.
- EGGENSPERGER, N.; SMOLKA, W.; IIZUKA, T. Long-term changes of hyoid bone position and pharyngeal airway size following mandibular setback by sagittal split ramus osteotomy. **Journal of Cranio-maxillo-facial Surgery**, v. 33, n. 2, p. 111-117, 2005.
- FROST, H, M. The Utah paradigm of skeletal physiology: an overview of its insights for bone, cartilage and collagenous tissue organs. **Journal of Bone and Mineral Metabolism**, v. 18, n. 6, p. 305-316, 2000.
- GOKCE, S. M.; GORGULU, S.; GOKCE, H. S.; BENGI, O.; SABUNCUOGLU, F.; OZGEN, F.; BILGIC, H. Changes in posterior airway space, pulmonary function and sleep quality, following bimaxillary orthognathic surgery. **International Journal of Oral and Maxillofacial Surgery**, v. 41, n. 7, p. 820-829, 2012.
- GOODDAY, R. Diagnosis, treatment planning, and surgical correction of obstructive sleep apnea. **Journal of Oral and Maxillofacial Surgery**, v. 67, n. 10, p. 2183-2196, 2009.

- GOSSETT, C. B.; PRESTON, C. B.; DUNFORD, R.; LAMPASSO, J. Prediction accuracy of computer-assisted surgical visual treatment objectives as compared with conventional visual treatment objectives. **Journal of Oral and Maxillofacial Surgery**, v. 63, n. 5, p. 609-617, 2005.
- GU, G. M.; GU, G.; NAGATA, J.; SUTO, M.; ANRAKU, Y.; NAKAMURA, K.; KUROE, K.; ITO, G. Hyoid position, pharyngeal airway and head posture in relation to relapse after the mandibular setback in skeletal Class III. **Clinical Orthodontics and Research**, v. 3, n. 3, p. 67-77, 2000.
- HOCHBAN, W.; SCHÜRSMANN, R.; BRANDENBURG, U.; CONRADT, R. Mandibular setback for surgical correction of mandibular hyperplasia - does it provoke sleep-related breathing disorders? **International Journal of Oral and Maxillofacial Surgery**, v. 25, n. 5, p. 333-338, 1996.
- JACOBSON, A. Airway changes after orthognathic surgery as assessed by cone-beam computed tomography. **American Journal of Orthodontics and Dentofacial Orthopedics**, v. 132, n. 5, p. 712, 2007.
- JOHAL, A.; CONAGHAN, C. Maxillary morphology in obstructive sleep apnea: a cephalometric and model study. **The Angle Orthodontist**, v. 74, n. 5, p. 648-656, 2004.
- JOHNS, F. R.; STROLLO, P. J. JR.; BUCKLEY, M.; CONSTANTINO, J. The influence of craniofacial structure on obstructive sleep apnea in young adults. **Journal of Oral and Maxillofacial Surgery**, v. 56, n. 5, p. 596-602, 1998.
- KITAGAWARA, K.; KOBAYASHI, T.; GOTO, H.; YOKOBAYASHI, T.; KITAMURA, N.; SAITO, C. Effects of mandibular setback surgery on oropharyngeal airway and arterial oxygen saturation. **International Journal of Oral and Maxillofacial Surgery**, v. 37, n. 4, p. 328-333, 2008.
- LAM, B.; OOI, C. G.; PEH, W. C.; LAUDER, I.; TSANG, K. W.; LAM, W. K. IP, M. S. Computed tomographic evaluation of the role of craniofacial and upper airway morphology in obstructive sleep apnea in Chinese. **Respiratory Medicine**, v. 98, n. 4, p. 301-307, 2004.
- LIUKKONEN, M.; VÄHÄTALO, K.; PELTOMÄKI, T.; TIEKSO, J.; HAPPONEN, R. P. Effect of mandibular setback surgery on the posterior airway size. **The International Journal of Adult Orthodontics and Orthognathic Surgery**, v. 17, n. 1, p. 41-46, 2002.
- MARSAN, G.; CURA, N.; EMEKLI, U. Changes in pharyngeal (airway) morphology in Class III Turkish female patients after mandibular setback surgery. **Journal of Cranio-maxillo-facial Surgery**, v. 36, n. 6, p. 341-345, 2008.
- MARSAN, G.; VASFI KUVAT, S.; OZTAS, E.; CURA, N.; SÜSAL, Z.; EMEKLI, U. Oropharyngeal airway changes following bimaxillary surgery in Class III female adults. **Journal of Cranio-maxillo-facial Surgery**, v. 37, n. 2, p. 69-73, 2009.
- MEHRA, P.; DOWNIE, M.; PITA, M. C.; WOLFORD, L. M. Pharyngeal airway space changes after counterclockwise rotation of the maxillomandibular complex. **American Journal of Orthodontics and Dentofacial Orthopedics**, v. 120, n. 2, p. 154-159, 2001.
- MUTO, T.; YAMAZAKI, A.; TAKEDA, S.; SATO, Y. Effect of bilateral sagittal split ramus osteotomy setback on the soft palate and pharyngeal airway space. **International Journal of Oral and Maxillofacial Surgery**, v. 37, n. 5, p. 419-423, 2008.
- PEREIRA-FILHO, V. A.; CASTRO-SILVA, L. M.; DE MORAES, M.; GABRIELLI, M. F.; CAMPOS, J. A.; JUERGENS, P. Cephalometric evaluation of pharyngeal airway space changes in class III patients undergoing orthognathic surgery. **Journal of Oral and Maxillofacial Surgery**, v. 69, n. 11, p. 409-415, 2011.
- POWER, G.; BRECKON, J.; SHERRIFF, M.; MCDONALD, F. Dolphin Imaging Software: an analysis of the accuracy of cephalometric digitization and orthognathic prediction. **International Journal of Oral and Maxillofacial Surgery**, v. 34, n. 6, p. 619-626, 2005.
- PRADO, F. B.; ROSSI, A. C.; FREIRE, A. R.; GROppo, F. C.; DE MORAES, M.; CARIA, P. H. Pharyngeal airway space and frontal and sphenoid sinus changes after maxillomandibular advancement with counterclockwise rotation for Class II anterior open bite malocclusions. **Dentomaxillofacial Radiology**, v. 41, n. 2, p. 103-109, 2012.
- SAITOH, K. Long-term changes in pharyngeal airway morphology after mandibular setback surgery. **American Journal of Orthodontics and Dentofacial Orthopedics**, v. 125, n. 5, p. 556-561, 2004.
- TSELNIK, M.; POGREL, M. A. Assessment of the pharyngeal airway space after mandibular setback surgery. **Journal of Oral and Maxillofacial Surgery**, v. 58, n. 3, p. 282-285, 2000.
- TURNBULL, N. R.; BATTAGEL, J. M. The effects of orthognathic surgery on pharyngeal airway dimensions and quality of sleep. **Journal of Orthodontics**, v. 27, n. 3, p. 235-247, 2000.

Received on June 29, 2013.

Accepted on July 30, 2013.

License information: This is an open-access article distributed under the terms of the Creative Commons Attribution License, which permits unrestricted use, distribution, and reproduction in any medium, provided the original work is properly cited.